

Myocardial Replacement Therapy

Tomasz Siminiak, MD, PhD, FESC; Maciej Kurpisz, MD, PhD

Case Presentation: A 56-year-old farmer who experienced a transmural anterior myocardial infarction (MI) 3 years ago was referred for evaluation of progressive dyspnea and fatigue. During the acute phase of MI, he was treated with fibrinolysis, as primary angioplasty was not available at his local hospital. Angiography performed 3 months after MI revealed occlusion of the left anterior descending artery with diffuse changes distal to the occluded segment. An attempt at percutaneous recanalization had failed. Despite treatment with β -blockers and angiotensin-converting enzyme inhibitors, serial echocardiograms performed by his local cardiologist had shown a large dyskinetic area and subsequently progressive dilatation and remodeling of the left ventricle. The patient is currently presenting with New York Heart Association class III symptoms and a history of several recent episodes of pulmonary edema.

Rationale for Myocardial Replacement Therapy

The development of postinfarction congestive heart failure in survivors of the acute phase of MI is related to myocardial cell loss in the area supplied by the infarct-related artery and

the subsequent formation of a scar. As the most important strategies during the acute phase of MI, primary angioplasty and fibrinolysis are aimed at the restoration of blood flow to minimize necrosis. In addition, late revascularization procedures may enable recovery of contractility, but only in areas of the hibernating myocardium that contain a minimal number of viable, reversibly injured myocytes. In patients with a large myocardial necrotic area resulting from acute MI, and especially when the necrotic zone is weakly supplied by collaterals, the loss of cardiomyocytes results in the formation of fibrous tissue and, subsequently, in left ventricular remodeling, aneurysm formation, and progression of congestive heart failure. In some patients, cardiac transplantation may be an option, but because of the shortage of organs, its practical use is limited to end-stage heart failure cases.

Stem cell implants have been discovered to exhibit regenerative properties for damaged organs, among them irreversibly damaged post-infarction regions of the myocardium. The classification of stem cells has also evolved. It must be stressed that totipotent stem cells in general express the potential to be differentiated into all 3 main embryonic layers (ectodermal,

endodermal, and mesodermal), whereas the committed progenitor cells belong to the tissue stem cell reservoir. However, it was recently proven that tissue progenitor cells may, under certain conditions, modify their ability for cell (tissue) differentiation into cells having characteristics different from cells in their primary location. Committed cells may change their characteristics dramatically and can thus be considered as the stem cells for tissue repair in distant locations, eg, hematopoietic cells into hepatocytes.¹ To simplify the origin of pluripotent cells, we may classify them into 3 main sources: (1) embryonic stem cells, (2) somatic totipotent stem cells (mostly originating from the bone marrow, but also identified in the cord blood samples), and (3) somatic progenitor cells of the tissue reservoir (eg, satellite cells, myoblasts).

Embryonic Stem Cells

Embryonic stem cells (ESCs) originate from the inner mass of the blastocyst or from primordial germ cells and can be propagated *in vitro* for a virtually unlimited time at the stage of totipotent ability, thus raising the possibility that they may be of use in the regeneration of every tissue and organ in the human body. Results of investigations

From the University School of Medical Sciences, Department of Cardiology, District Hospital (T.S.), and the Institute of Human Genetics, Polish Academy of Sciences (M.K.), Poznań, Poland.


Correspondence to Prof Tomasz Siminiak, MD, PhD, FESC, FACC, University School of Medical Sciences, Department of Cardiology, District Hospital, ul. Juraszow 7/19, PL 60- 479 Poznań, Poland. E-mail tomasz.siminiak@usoms.poznan.pl

(*Circulation*. 2003;108:1167-1171.)

© 2003 American Heart Association, Inc.

Circulation is available at <http://www.circulationaha.org>

DOI: 10.1161/01.CIR.0000086628.42652.8D



in this area confirm that, depending on the specific microenvironment, ESCs may mature and acquire all the characteristics of the target tissue. The instrumentation of ESC delivery, eg, via a blastocyst or clone reconstructed from the diploid nucleus and enucleated oocyte,² is a topic of debate. Because ESCs tend to imitate the physiological as well as the pathological environment, they therefore can be subjected to the influence of the surrounding tissue, eg, in a scar in the postinfarction heart, they can be differentiated into connective tissue cells. The plasticity of ESC and the other sources of stem cells have become a matter of considerable significance in the study of organ regeneration.

Bone Marrow Cells

Bone marrow cells (BMCs) are almost equal to ESCs in their ability for pluripotent cell differentiation. These cells display a significant degree of heterogeneity and include bone marrow-residing hematopoietic stem cells (HSCs) and mesenchymal stem cells (MSCs), which are also known as stromal stem cells (SSCs), as well as progenitor cells for different tissues. The potential ability to restore both myogenesis and cardiomyogenesis can be ascribed to both of these main cell subsets.³ BMCs, as well as their cord blood counterparts, are now under investigation regarding their plasticity, eg, their potential to restore the capacity of target tissues, including myocardium. A number of cell markers, including CD 34 or KDR, that probably reflect the totipotent ability of BMCs have been delineated.⁴ Subfractions of cells either sharing these markers or indicating a separate cell origin appear to subdivide HSCs into endothelial-hematopoietic stem cells that seem to possess different cardiomyocyte potential. In general, experimental data suggest that the plasticity of BMCs may result in their differentiation into cell lines similar to the surrounding tissue and, as such, BMCs are more widely accepted for use in

areas of fresh myocardial injury, ie, before the scar has had time to form.

Tissue Stem Cells

Tissue stem cells (TSCs) have become one of the most interesting targets for the study of organ regeneration because of their limited plasticity. Among them, cells from different sources have been applied for postinfarction heart regeneration.⁵

Cardiomyocytes

These cells have been extensively utilized in preclinical studies. The results of transplantation of these cells were dependent upon whether they were obtained from adults or were of fetal origin. Although transplanted mature cardiomyocytes were thought to cooperate well with endogenous cardiomyocytes, this was not the case when fully mature cells were implanted. Furthermore, it was found that only fetal cardiomyocytes can form fully compatible gap junctions and functioning implants.⁶ It has to be emphasized that in regard to a non-inbred human population, the use of fetal origin cardiomyocytes would be ethically questionable and, secondly, allogenic cell implants could not be used in clinical practice because of alloimmune reactions occurring between cells originating from different individuals.

Fibroblasts

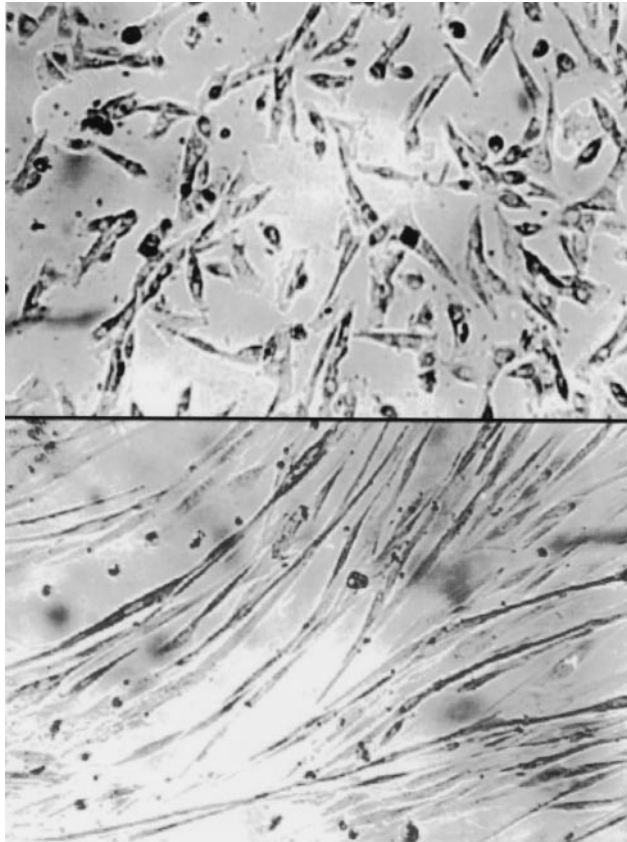
After the application of gene transfer technology with the help of adenovirus vector,⁷ it was found that isolated human fetal fibroblasts that had been transfected with a construct containing MyoD resulted in a phenotype with immunochemical and morphological characteristics similar to muscle cells. These cells were then delivered to immunocompromised mice, where the cells formed normal tubules with contractile properties. Preclinical studies suggest that, even if not genetically modified to obtain muscle-like phenotype, fibroblast transplantation into damaged myocardium may strengthen the scar and therefore prevent left ventricular remodeling.⁸

Myoblasts

The most interesting committed progenitor cells are the tissue reservoir cells known as satellite cells. Satellite cells (skeletal myoblasts) are located in the basal lamina of adult skeletal muscle. In both preclinical studies and in safety clinical trials, they appear to repopulate the irreversibly damaged postinfarction area. Their limited plasticity has been seen as an advantage over the more environmentally vulnerable totipotent stem cells (Figure). Experimental data suggest that only myoblasts are capable of forming myocyte-like elements and of improving the contractile performance of the left ventricle after transplantation into an "old" postinfarction scar, ie, with necrotic myocytes being replaced by fibrous tissue.⁵ Although originating from skeletal muscle, myoblasts form intercalated discs in the heart with a loose association with original cardiomyocytes. In functional experimental studies, however, myoblasts seemed to increase the ejection fraction. As autologous cells of the skeletal reservoir, myoblasts do not pose either ethical difficulties or an immunological hazard. Several studies have shown that both systolic and diastolic function have been improved as a result of skeletal myoblast transplantation into the area of the damaged myocardium,^{5,8,9} despite the fact that clear evidence suggests that differentiated skeletal muscle grafts do not express N-cadherin or connexin 43, two proteins involved in electromechanical coupling between cardiac myoblasts.⁵ Intensive studies aimed at improving cooperation between myoblasts and cardiomyocytes in response to synchronous electrophysiological stimuli, including studies using conditioned gene transfer technologies, are ongoing.

Clinical Experience With Cell Transplantation for Myocardial Regeneration

The possible therapeutic use of embryonic or fetal stem cells raises serious political, ethical, and even religious



Non-stained photographs of preparations from *in vitro* cell culture (magnification 200 \times). Myoblasts used for transplantation (above) and preparation confirming the cultured myoblasts' capability of transformation into myocytes *in vitro* in serum-free conditions (below).

issues, and therefore it is some way from clinical application. The use of cells from allogenic sources, including cell lines, would require immunosuppression. Currently, therefore, only autologous bone marrow stem cells and skeletal myoblasts are being studied as possible cells for myocardial regeneration in patients with postinfarction heart failure.

Bone Marrow Cell Transplantation

Experimental data have shown that bone marrow cells are capable of improving the contractile performance of infarcted myocardium by inducing myogenesis and angiogenesis.^{8,9} This is supported by evidence that several different fractions of mononuclear BMCs may differentiate into endothelium and smooth muscle cells, as well as into cardiac myocytes. Furthermore, transendothelial migration of bone-

marrow-derived cells from coronary capillaries and incorporation into heart muscle has been observed experimentally.¹⁰

Findings from preclinical studies resulted in the initiation of clinical trials to evaluate the use of autologous BMCs for myocardial regeneration. Evidence for extravasation of BMCs from coronary capillaries into damaged myocardium has encouraged several groups, including Strauer et al,¹¹ to perform the intracoronary administration of autologous mononuclear bone marrow cells in patients who survived an acute MI. The cells were delivered directly into the infarct-related coronary artery via an angioplasty balloon catheter under high pressure. In 10 BMC recipients in this phase I clinical trial, improvements in stroke volume index, left ventricular end systolic volume, and contractility were observed 3 months after cell

transplantation, compared with patients receiving standard treatment.¹¹ A phase I clinical trial on autologous BMC transplantation performed together with coronary artery bypass grafting (CABG) was reported by Stamm et al.¹² They used AC133 positive cells, a more specified subpopulation of bone-marrow derived cells, for intra-myocardial injections performed during an open-chest procedure and observed increased left ventricular ejection fraction and improved tissue perfusion during follow-up.

Because totipotent stem cells after transplantation could differentiate into more mature cell types depending on information from the surrounding microenvironment, the effect of BMC transplantation in postinfarction myocardial regeneration may be related to the time of cell delivery after the onset of infarction. Experimental data suggest that administration of BMCs very early after infarction may not increase myocardial contractile performance,¹³ and it may be speculated that cell transplantation during the inflammatory phase of myocardial healing could result in the involvement of BMCs in the inflammatory reaction itself. On the other hand, very late BMC transplantation into a fibrous postinfarction scar may result in their differentiation into fibroblasts.^{14,15} Despite these observations, a clinical study evaluating injections of bone marrow cell suspension during CABG several months after an acute MI has been performed and suggests a beneficial effect.¹⁶ This was followed by a paper by Perin et al¹⁷ evaluating percutaneous intramyocardial injections of autologous BMCs with the NOGA system in patients with heart failure weeks to months after acute MI. Increased perfusion was detected on single photon emission computed tomography and increased ejection fraction was observed through echocardiography.

Current evidence indicates that autologous BMCs may be used for myocardial regeneration early (ie, 2 to 3 days to a few weeks) after infarction. These cells are capable not only of

differentiation into myocytes but also of contribution to the formation of new vessels, and their potential therapeutic use seems therefore to be very attractive. In addition, no side effects, especially no significant arrhythmogenic effects, of BMC transplantation have been reported so far. However, clear evidence of formation of new cardiac myocytes after BMC transplantation into an old, fibrous postinfarction scar is missing.

Skeletal Myoblast Transplantation

Skeletal myoblasts have been extensively studied as possible cells for transplantation into damaged myocardium. Several investigators have produced clear evidence indicating adequate survival and engraftment of autologous skeletal myoblasts in infarcted myocardium. Skeletal myoblasts are highly resistant to ischemia and, after transplantation even into fibrous scar, they do form myocyte-like cells with their appropriate orientation.^{5,9} Numerous experimental studies have shown improved systolic and diastolic performance as a result of the transplantation of skeletal myoblasts into the area of myocardial injury, irrespective of the method used to assess function in vitro (dP/dt or force transduction) or in vivo (sonomicrometry, echocardiography) and regardless of the species studied (rat, rabbit, dog, pig, sheep) or the model of myocardial injury (reviewed in references 5, 8, and 9).

These encouraging preclinical data have led to clinical trials. After the first-in-human experience by Menasché et al,¹⁸ we have performed an independent phase I clinical trial on autologous skeletal myoblast transplantation in patients undergoing CABG.^{19,20} MI survivors, with an akinetic area of the left ventricle and scheduled for CABG, were screened by means of dobutamine stress echocardiography and included in the study when no viable myocardium was detected. A skeletal myocardial biopsy was obtained from the vastus lateralis in all patients. The biopsy sample was

digested with collagenase I and myoblasts (satellite cells) were isolated. The cells were cultured for 3 weeks and up to 2×10^7 myoblasts per patients were grown. Myoblast injections into the akinetic area were done after constriction of the anastomoses during the CABG procedure. An increase in segmental contractility was seen in all patients 2 to 3 months after the procedure, and this effect was maintained throughout a 12-month follow-up period. It should be noted that in studies on cell transplantation performed during CABG, including the phase I observations of Menasché et al¹⁸ and our own, despite the use of careful inclusion criteria aimed at selection of patients with no viable myocardium within the area of postinfarction injury, the possible effect of skeletal myoblast transplantation may be enhanced by myocardial revascularization. Studies with percutaneous myoblast delivery with no concomitant revascularization are ongoing.

Transplantation of autologous skeletal myoblasts into an old, fibrous postinfarction scar may result in the generation of ventricular arrhythmias. A postinfarction scar is an arrhythmia substrate itself, and the insertion of muscle cells into the scar may further disturb its electrophysiological homogeneity. In our phase I study, we observed sustained ventricular tachycardia episodes in 2 patients during their early postoperative period and in 2 other patients during Holter monitoring at their 2-week follow-up visit. We used prophylactic amiodarone infusions in all of our other patients, and this prevented any other episodes of ventricular tachycardia. No amiodarone was used 3 months after transplantation. Similarly, data from the phase I clinical study by Menasché et al¹⁸ indicate that the possible arrhythmogenic effect of myoblast transplantation was observed only in the initial weeks after the procedure. Thus, the possible arrhythmogenic effect of myoblast transplantation is more probably related to its mechanics, including myocardial puncture or the inflammatory response to transplanted cells, some of which die after injection, than to

possible problems with electromechanical coupling between newly developed myocytes and cardiomyocytes. Possible electromechanical coupling problems would result in late arrhythmia as cells differentiate, a situation that has not been observed in clinical trials so far.

Conclusion

Myocardial replacement therapy for the treatment of patients with postinfarction heart failure is feasible, and initial observations justify further research, particularly involving controlled clinical trials, to validate the method and to define its role in clinical practice. Current data indicate that, for clinical application, bone marrow cells may be the best option when transplanted early after infarction, whereas autologous skeletal myoblast transplantation may be capable of restoring contractile performance within a fibrous postinfarction scar.

References

1. Lagase E, Connors H, Al-Dhalimy M, et al. Purified hematopoietic stem cells can differentiate into hepatocyte in vivo. *Nature Med*. 2000;6:1229–1231.
2. Thomson JA, Itskovits-Eldor J, Shapiro SS, et al. Embryonic stem cell lines derived from human blastocyst. *Science*. 1998;282:1145–1147.
3. Gussoni E, Soneoka Y, Strickland CD, et al. Dystrophin expression in the mdx mouse restored by stem cell transplantation. *Nature*. 1999;401:390–394.
4. Ziegler BL, Valtieri M, Porada GA, et al. KDR receptor: a key marker defining hematopoietic stem cells. *Science*. 1999;285:1553–1558.
5. Taylor DA. Cellular cardiomyoplasty with autologous skeletal myoblasts for ischemic heart disease. *Curr Control Trials Cardiovasc Med*. 2001;2:208–210.
6. Zhang M, Methot D, Poppa V. Cardiomyocyte grafting for cardiac repair: graft cell death and anti-death strategies. *J Mol Cell Cardiol*. 2001;33:907–921.
7. Lattanzi L, Salvatori G, Coletta M. High efficiency myogenic conversion of human fibroblasts by adenoviral vector-mediated MyoD gene transfer: an alternative strategy for ex vivo gene therapy of primary myopathies. *J Clin Invest*. 1998;101:2119–2128.
8. El Oakley RM, Ooi OC, Bongso A, et al. Myocyte transplantation for myocardial repair: a few good cells can mend a broken heart. *Ann Thorac Surg*. 2001;71:1724–1733.
9. Hagège AA, Vilquin JT, Bruneval P, et al. Regeneration of the myocardium: a new role in treatment of ischemic heart disease? *Hypertension*. 2001;38:1413–1415.



10. Wang JS, Shum-Tim D, Chedrawy E, et al. The coronary delivery of marrow stromal cells for myocardial regeneration: pathophysiological and therapeutic implications. *J Thorac Cardiovasc Surg.* 2001;126:699–705.
11. Strauer BE, Brehm M, Zeus T, et al. Repair of infarcted myocardium by autologous intracoronary mononuclear bone marrow cell transplantation in humans. *Circulation.* 2002;106:1913–1918.
12. Stamm C, Westphal B, Kleine KD, et al. Bone marrow stem cell transplantation for myocardial regeneration in post-infarction CABG patients. *Circulation.* 2002;106(suppl II):II-375. Abstract.
13. Li RK, Mickle DA, Weisel RD, et al. Optimal time for cardiomyocyte transplantation to maximize myocardial function after left ventricular injury. *Ann Thorac Surg.* 2001;72:1957–1963.
14. Wang J-S, Shum-Tim D, Chedrawy E, et al. Marrow stromal cells for cellular cardiomyoplasty: the importance of microenvironment for milieu dependent differentiation. *Circulation.* 2000;102(suppl II):II-683. Abstract.
15. Bel A, Messas E, Onnik A, et al. Transplantation of autologous fresh bone marrow into infarcted myocardium: a word of caution. *Circulation.* 2002;106(suppl II):II-463. Abstract.
16. Galinanes M, Loubani M, Davies J, et al. Safety and efficacy of transplantation of autologous bone marrow into scarred myocardium for the enhancement of cardiac function in man. *Circulation.* 2002;106(suppl II):II-463. Abstract.
17. Perin EC, Dohmann HFR, Borojevic R, et al. Transendocardial, autologous bone marrow cell transplantation for severe, chronic ischemic heart failure. *Circulation.* 2003;107:2294–2302.
18. Menasché P, Hagege AA, Scorsin M, et al. Myoblast transplantation for heart failure. *Lancet.* 2001;357:279–280.
19. Siminiak T, Kalawski R, Kurpisz M. Myoblast transplantation in the treatment of postinfarction myocardial contractility impairment: a case report. *Kardiol Pol.* 2002;56:131–136.
20. Siminiak T, Kalawski R, Fiszer D, et al. Transplantation of autologous skeletal myoblasts in the treatment of patients with postinfarction heart failure. *Circulation.* 2002;106(suppl II):II-636. Abstract.